

# Cystic Brain Metastases in NSCLC Harboring the EML4-ALK Translocation after Treatment with Crizotinib

Christine Saraceni, DO,\* P. Mark Li, MD,\* Justin F. Gainor, MD,† Gary A. Stopyra, MD,\* and Eliot L. Friedman, MD\*

## CASE OF THE MONTH SUBMISSION

A 39-year-old woman nonsmoker presented in August 2007 with chest wall discomfort. Computed tomography (CT) revealed right upper lobe parenchymal and pleural abnormalities as well as mediastinal lymphadenopathy. Bronchoscopy and mediastinoscopy yielded a diagnosis of adenocarcinoma of the lung. No mutations in *KRAS* or epidermal growth factor receptor (*EGFR*) were identified.

She received four cycles of carboplatin, paclitaxel, and bevacizumab followed by maintenance bevacizumab and erlotinib. Her tissue was reanalyzed and an anaplastic lymphoma kinase (*ALK*) rearrangement was detected. After disease progression in March 2011, she began crizotinib 250 mg orally twice daily on a phase II clinical trial (PROFILE 1005), ultimately achieving a complete remission. Initial magnetic resonance imaging (MRI) imaging of the brain was negative.

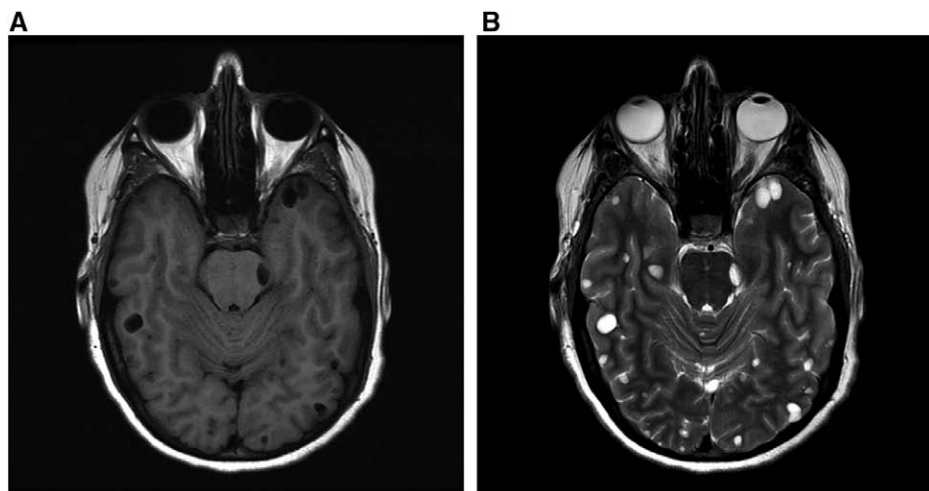
In July 2011, she developed pupil asymmetry. MRI of the brain revealed multiple, bilateral, cystic lesions without pathological enhancement. Lumbar puncture was unremarkable.

Crizotinib was continued. She received Cyberknife therapy to a lesion in the thalamus and the other lesions were observed.

In September 2013, MRI of the brain demonstrated progression in size and number of the parenchymal cystic brain lesions (Fig. 1A, B). A CT scan of the chest and abdomen done at that time demonstrated disease stability. She underwent image-guided frontal craniotomy with biopsy of two cystic lesions. Pathology confirmed metastatic lung adenocarcinoma. The patient declined whole brain radiation therapy and began treatment with ceritinib (LDK387) in January 2014. An MRI of the brain performed in September 2014 demonstrated reduction of the previously noted brain metastases (Fig. 2). A chest-CT scan demonstrated continued stability of her systemic disease at that time.

## DISCUSSION

The *ALK* rearrangement defines a distinct molecular subgroup within non-small-cell lung cancer. Its discovery has spurred the development of multiple molecular targeted



**FIGURE 1.** A, B, MRI showing multiple varying-sized cystic lesions within the brain parenchyma (A) axial T1 flair, (B) axial T2-postcontrast. MRI, magnetic resonance imaging.

\*Lehigh Valley Health Network, Allentown, PA; †Massachusetts General Hospital, Boston, MA; and ‡Health Network Laboratories, Lehigh Valley Health Network, Allentown, PA.

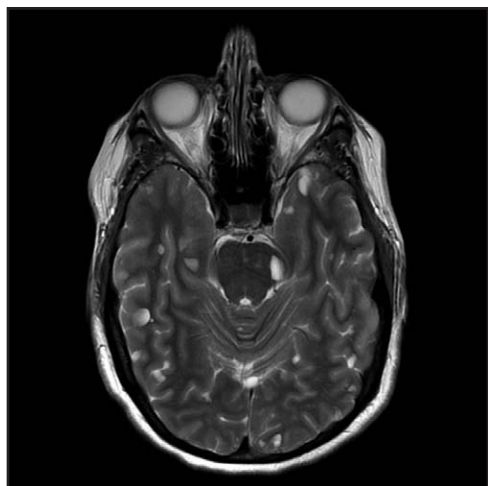
Disclosure: The authors declare no conflict of interest.

Address for Correspondence: Eliot L. Friedman, MD, Division of Hematology and Medical Oncology, 1240 S. Cedar Crest Blvd, Suite 401, Allentown, PA 18103. Email: Eliot\_L.Friedman@lvhn.org

DOI: 10.1097/JTO.0000000000000409

Copyright © 2014 by the International Association for the Study of Lung Cancer

ISSN: 1556-0864/15/1007-1116



**FIGURE 2.** MRI of the brain showing cystic brain metastases throughout the brain parenchyma that appears grossly unchanged or slightly decreased in size after 7 months of treatment with ceritinib (axial T2-postcontrast). MRI, magnetic resonance imaging.

agents, including crizotinib and ceritinib. Despite the therapeutic efficacy of crizotinib,<sup>1</sup> patients will ultimately develop resistance to therapy, usually in the central nervous system.<sup>2-6</sup> In addition, the cystic appearance of the brain metastases in our patient, as well as in two other case reports,<sup>3</sup> describes a unique radiographic pattern in patients with ALK positivity.

This is the first case report with pathologic assessment of cystic central nervous system (CNS) lesions in patients taking crizotinib. Contrary to the first case report, which proposed a potential link between signet ring histology and cystic brain lesions,<sup>3</sup> there were no signet ring cells in the CNS specimen in our case. This is also the first case report to explore the mechanism of resistance in CNS lesions resistant to crizotinib. Targeted next-generation sequencing, utilizing the T5a test sequencing 287 genes was performed (Foundation One, Foundation Medicine Inc., Cambridge, MA). No *ALK* resistance mutations were identified in the brain metastasis sample. No additional mutations imparting resistance were identified,<sup>7,8</sup> raising the possibility of low CNS levels of crizotinib imparting resistance to the drug.<sup>9</sup>

The next-generation *ALK* inhibitor ceritinib recently received accelerated approval for the treatment of *ALK*-positive patients resistant to and/or intolerant to crizotinib. In the phase I study of ceritinib, responses were observed in patients with brain metastases.<sup>10</sup> Of note, the median progression-free survival after treatment with ceritinib was similar among patients with and without CNS metastases. Thus, the stability of the CNS lesions on ceritinib in our patient may reflect better CNS penetration.

Recently, several other next-generation *ALK* inhibitors with promising CNS activity have been developed. In a phase I/II study of the novel *ALK* inhibitor alectinib, objective responses in the CNS were observed in 11 of 21 (52%) patients with brain metastases. Cerebrospinal fluid sampling in five patients documented alectinib penetration into the cerebrospinal fluid compartment.<sup>11</sup> Early studies of the next-generation *ALK* inhibitor AP26113 have also shown tumor regressions in 9 of 13 (69%) patients with untreated or progressing brain metastases.<sup>12</sup> Moving forward, additional prospective data is needed to inform the duration of CNS responses in patients treated with second-generation *ALK* inhibitors and provide a better sense of the denominators of patients with CNS lesions treated with these agents.

## REFERENCES

1. Malik SM, Maher VE, Bijwaard KE, et al. U.S. Food and Drug Administration approval: Crizotinib for treatment of advanced or metastatic non-small cell lung cancer that is anaplastic lymphoma kinase positive. *Clin Cancer Res* 2014;20:2029–2034.
2. Chun SG, Choe KS, Iyengar P, et al. Isolated central nervous system progression on crizotinib. An Achilles heel of non-small cell lung cancer with EML4-*ALK* translocation? *Cancer Biol Ther* 2012;13:1376–1383.
3. Hayashi H, Okamoto I, Tanizaki J, et al. Cystic brain metastasis in non-small cell lung cancer with *ALK* rearrangement. *J Clin Oncol* 2014;32:1–3.
4. Takeda M, Okamoto I, Nakagawa K. Clinical impact of continued crizotinib administration after isolated central nervous system progression in patients with lung cancer positive for *ALK* rearrangement. *J Thorac Oncol* 2013;8:654–657.
5. Gainor JF, Ou SH, Logan J, Borges LF, Shaw AT. The central nervous system as a sanctuary site in *ALK*-positive non-small-cell lung cancer. *J Thorac Oncol* 2013;8:1570–1573.
6. Camidge DR, Bang Y-K, Kwak EL, et al. Activity and safety of crizotinib in patients with *ALK*-positive non-small-cell lung cancer: Updated results from a phase 1 study. *Lancet Oncol* 2012;13:1011–1019.
7. Katayama R, Shaw AT, Khan TM, et al. Mechanisms of acquired crizotinib resistance in *ALK*-rearranged lung cancers. *Sci Transl Med* 2012;4:12–17.
8. Gainor JF, Shaw AT. Emerging paradigms in the development of resistance to tyrosine kinase inhibitors in lung cancer. *J Clin Oncol* 2013;31:3987–3996.
9. Costa DB, Kobayashi S, Pandya SS, et al. CSF concentration of the anaplastic lymphoma kinase inhibitor crizotinib. *J Clin Oncol* 2011;29:e443–e445.
10. Shaw AT, Kim DW, Mehra R, et al. Ceritinib in *ALK*-rearranged non-small-cell lung cancer. *N Engl J Med* 2014;370:1189–1197.
11. Gadgeel SM, Gandhi L, Riely GJ, et al. Safety and activity of alectinib against systemic disease and brain metastases in patients with crizotinib-resistant *ALK*-rearranged non-small-cell lung cancer (AF-002JG): Results from the dose-finding portion of a phase 1/2 study. *Lancet Oncol* 2014;15:1119–1128.
12. Gettinger SN, Bazhenova L, Salgia R, et al. Updated efficacy and safety of the *ALK* inhibitor AP26113 in patients (pts) with advanced malignancies, including *ALK*+ non-small cell lung cancer (NSCLC). *J Clin Oncol* 2014;32:5s (suppl; abstr 8047).